

Skeletal Pathology in Fishes

**Siddhnath¹, Shiv Mohan Singh^{1*}, Ravikant Bharti¹, Abdul Aziz², Bhogeshwar Chirwatkar³,
Narinder Kaur⁴**

Dept. of Fish Processing Technology, Faculty of Fishery Sciences, WBUAFS Kolkata¹

Dept. of Fisheries Economics and Statistics, Faculty of Fishery Sciences, WBUAFS Kolkata²

Dept. of Aquatic Environment Management, Faculty of Fishery Sciences, WBUAFS Kolkata³

Central Institute of Fisheries Education, Mumbai⁴

Abstract: A skeleton of fish consists of the vertebral column, jaw, ribs, cranium and intramuscular bones. It provides protection and control and also they produce red blood cells in addition to kidneys and spleen. Starting from the head, bony fish consist of solid hard bones called cranium. Cranium protects the brain from mechanical stresses. Osteichthyes have hinged jaws which aid them in feeding. But fishes like hagfish, lampreys are jawless fishes. Swim bladders help them to take up the dissolved oxygen from water and provide buoyancy. Otoliths are unique characteristics of ear plates of bony fish which helps in steadiness. Disease like Whirling disease destroys this steadiness. skeletal damage in fishes is also associated to be nutritional like Ascorbic acid (vitamin C) deficiency and Phosphorus deficiency. Bacteria (like Dissolving head disease) and Virus (Like Pike fry virus disease) also find their role in piscine skeletal pathology. Mycotic infection is also been observed in fishes skeleton. Exposure to range of toxicants negatively affect skeleton of pisces. Vertebral column fracture, associated with electrocution or lightning strike may break the spinal column at the flexure point. Understanding piscine skeletal pathology will pave the way to minimize economical losses due to unappealing appearance and explore new suitable remedials.

Keyword: Fish, Skeleton, Cranium, Bacteria, Virus.

1. INTRODUCTION

The microscopic structural elements of fish bones are similar to those of other vertebrates and generally two types of bone are found, cellular and acellular. The former contains osteocytes and is confined to lower orders, such as Clupeidae, Salmonidae and Cyprinidae. Acellular bone is unique in vertebrates; it contains no osteocytes and is found in advanced teleosts such as Percidae and Centrarchidae, often having a solid featureless matrix. The lack of cells has been shown to preclude resorption of calcium from the bones so that acellular bones cannot function as a calcium reserve. Repair of fractures under acalcaemic conditions in advanced teleosts is therefore hindered. Despite the presence of vascular canals and 'marrow' spaces in some bones of both main types, no haemopoietic tissue is present in such spaces. The structure of teleost bone, without a marrow cavity and haversian system, means that osteomyelitis cannot exist, and inflammation, in an avascular solid tissue, can only develop from the adjacent periosteal vessels, and generally takes the form of rarefaction rather than frank osseous necrosis.

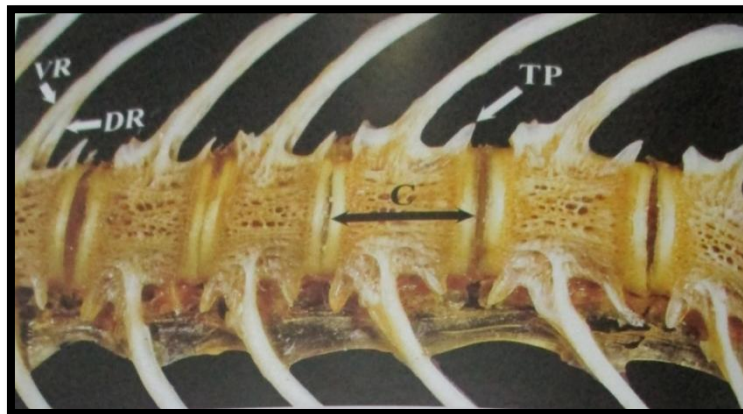


Fig 1: This image is of the ventral aspect of the spinal column in the abdominal region. The spongy bone of the centra (C) is clearly visible as are the intravertebral spaces between the centra and the transverse processes (TP). The ventral (VR) and dorsal ribs (DR) are visible only in some areas. Behind the abdominal cavity the ventral ribs fuse to form the haemal arch. (By courtesy of Dr. T. T. Poppe.)

2. WHIRLING DISEASE

Whirling disease, infection of the cranial and vertebral cartilages, prior to ossification, by the spores of *Myxobolus cerebralis*, induces a rarefying necrosis of the cranial cartilages which, when they ossify, do so in a malformed way. The initial damage and the subsequent ossification result in both skeletal deformity, manifested by spinal curvature and foreshortening, and interference with nerve and sensory organ function. Thus the clinical manifestation of extreme darkening in colour and whirling movements reflect pressure on spinal nerves and damage to semicircular canals, respectively.




Fig 2: “Whirling disease” showing cranial bone-cartilage interface. Foci of chondrolysis that contain various stages of developing myxozoa. A maturing spore is shown (arrow) . The bone is relatively normal. (By courtesy of Dr. Ferguson.)

3. SKELETAL DAMAGE ASSOCIATED WITH ASCORBIC ACID (VITAMIN C) DEFICIENCY

Ascorbic acid is an essential co-factor for the hydroxylation of the amino acids, proline and lysine, essential for normal maturation of collagen. Thus deficiency collagen metabolism induced by vitamin C deficiency, particularly in rapidly growing cultured fish, produces spinal deformity.

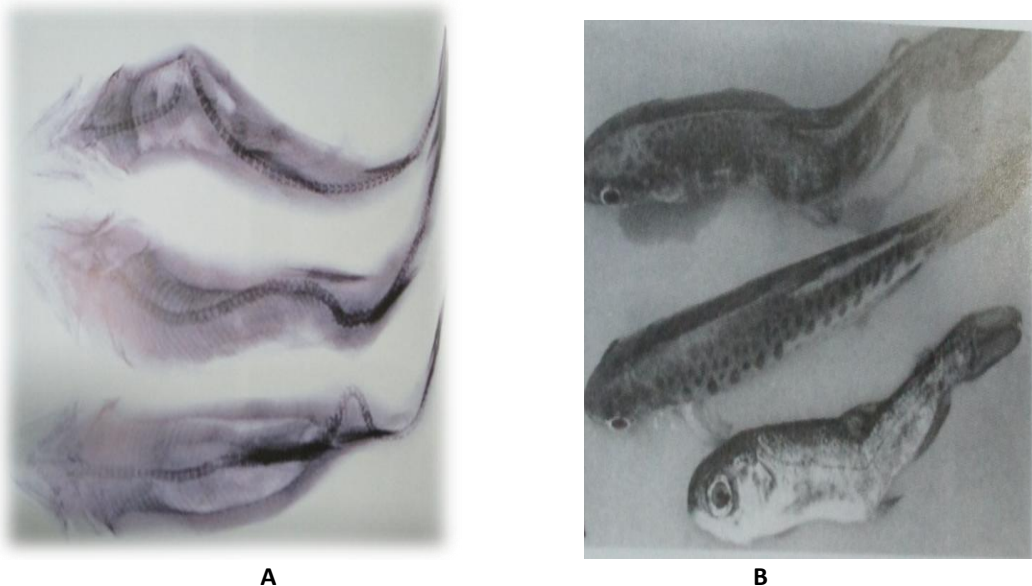


Fig 3 (A) (B): Spinal deformity due to fed diet deficient in ascorbic acid. Right hand side figure shows: Scoliosis is present in the upper fish, lordosis in the bottom fish. The middle fish is normal. (By courtesy of Dr. John Halver.)

4. SKELETAL DAMAGE ASSOCIATED WITH PHOSPHORUS DEFICIENCY

Fish with phosphate deficiency have characteristic soft, rubbery bones, due to failure of ossification, often accompanied by cervical or lumbar vertebral fractures. There is also a very characteristic pathognomonic, distinctive twisted dorsal spinous process.

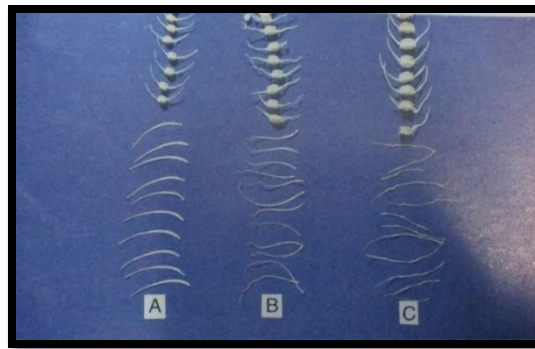


Fig 4: Spinal vertebrae on phosphorus deficient diets. A = normal rainbow trout, B = experimental deficiency in rainbow trout, C = deficiency in farmed Atlantic salmon. The deformity is principally in the dorsal spinous processes of the vertebrae. (By courtesy of Dr. Shozo Sugiura.)

5. SCREAMER DISEASE

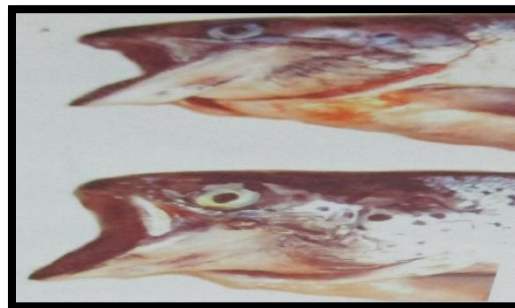


Fig 5: 'Screamer disease' in farmed Atlantic salmon. The opercula are fixed open due to ankylosis of the mandibular articulation, the end result of phosphorus imbalance. (By courtesy of Dr. T. T. Poppe.)

6. BACTERIA SHOWING SKELETAL PATHOLOGY

Yellow-pigmented bacteria such as *Flavobacterium psychrophilum* lyses cranial cartilage in young fish (give the colorful name of dissolving head disease); scleral cartilage is also affected which leads to exophthalmia. Spinal column is also involved and in particular intervertebral discs, leading to deformity in surviving fish.

7. DISSOLVING HEAD DISEASE

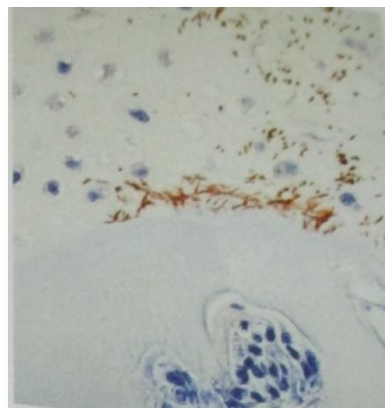


Fig 6: Yellow-pigmented bacteria *Flavobacterium psychrophilum* infection of the cranial cartilage. Note how the bacteria favor the cartilage rather than bone. (By courtesy of Dr. V. E. Ostland.)

8. EXPOSURE TO RANGE OF TOXICANTS

Vertebral developmental anomalies associated with exposure to zinc, organochlorine, organophosphate, and carbamate results from a primary effect on cardiac conduction. In some cases there may be very distinctive vertebral dysplasia as a

result of exposure of sheepshead minnows to the herbicide trifluralin. The condition resulted in osseous hyperplasia, as result of retention or proliferation of osteoblast within the vertebral bodies.

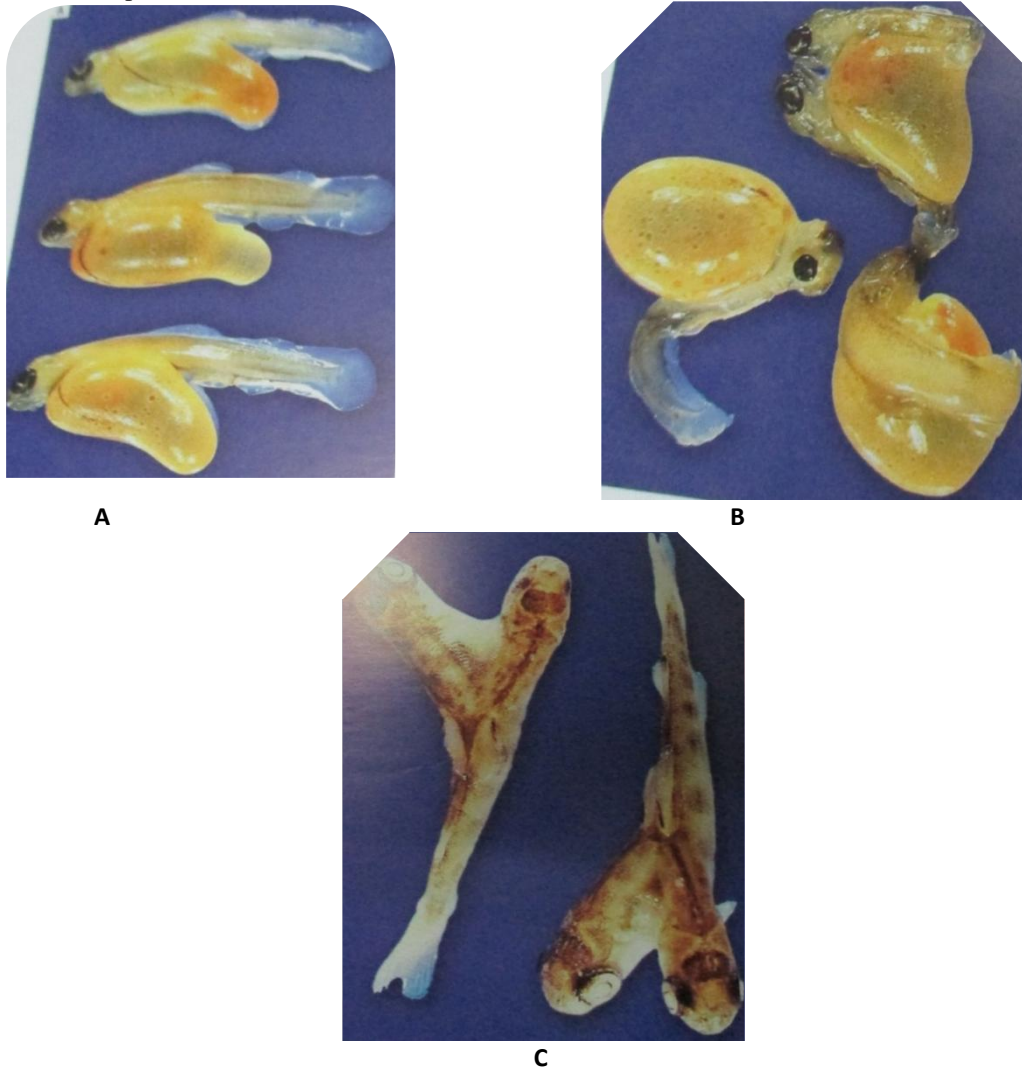


Fig 7: A-C show yolk-sac trout larvae. Those in A are normal, while B shows a range of abnormalities. Those in C show Siamese twinning. (By courtesy of Dr. Ferguson.)

9. VERTEBRAL COLUMN FRACTURE, ASSOCIATED WITH ELECTROCUTION OR LIGHTNING STRIKE.

Severe contraction of the body muscle may break the spinal column at the flexure point.

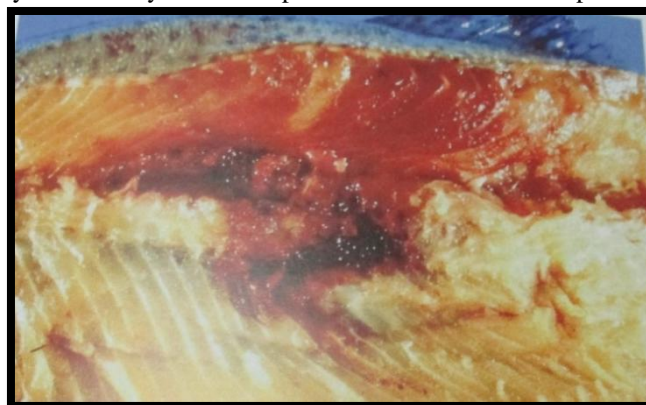


Fig 8: Rainbow trout showing fractured spinal column, the result of electrocution due to lightning strike. This would have caused marked contraction of muscles; fracture just below the dorsal fin is the commonest location for such lesions, presumably because this is the fulcrum for contraction. (By courtesy of R. D. Moccia.)

10. PIKE FRY VIRUS DISEASE

It is caused by a single rhabdovirus now called Pike Fry Rhabdovirus (PFRV). Hydrocephalus common in very young fry, moderate to severe swelling caused by oedema occurs in the central dorsum of the head behind the eyes in conjunction with exophthalmia. Histological examination revealed haemorrhage in the connective tissue in the spinal cord.

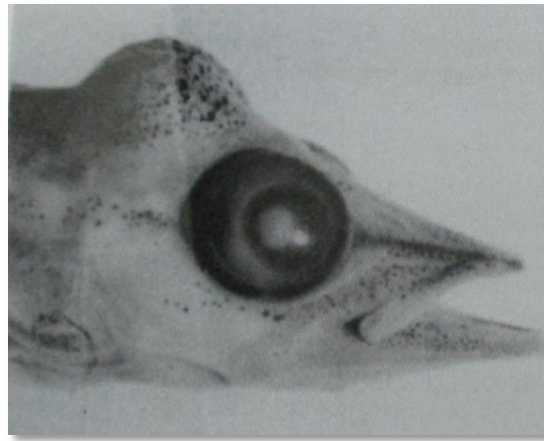


Fig 9: Pike fry virus disease. Head of young pike showing gross cranial distension. (By courtesy of Dr R. Bootsma.) Any disease causes severe damage to muscle will eventually distort the skeleton. Anesthetics may aid in differentiating between muscular or neural lesions and those of the skeleton. If the skeleton abnormality disappears or greatly lessens during anesthesia, it is more likely that the lesion is muscular.

11. VARIOUS SYMPTOMS OF SKELETAL PATHOLOGY IN FISHES

- **Ankylosis:** Abnormal stiffening and immobility of a joint due to fusion of the bone.
- **Ankylosing spondylitis (AS):** It refers to inflammation of the joints in the spine. As is also known as rheumatoid spondylitis or Marie-Strumpell disease.
- **Caseonecrotic changes:** Cell death - tissue maintains cheese-like appearance.
- **Contracture:** A condition of shortening and hardening of muscles, tendons, or other tissue, often leading to deformity and rigidity of joints.
- **Disc Luxation:** Dysfunction in the temporomandibular joint are generally associated with displacement of the articular disc.
- **Fascia:** Thin sheath of fibrous tissue enclosing muscle or other organ.
- **Fibrosis:** Formation of excess fibrous connective tissues in an organ or tissue in a reparative or reactive process.
- **Infarct:** A small localized area of dead tissue resulting from failure of blood supply.
- **Inspissation:** Plugging of a tubular lumen – thick or thickened in consistency.
- **Kyphosis:** Excessive outward curvature of the spine, causing hunching of the back.
- **Lesion:** A region in an organ or tissue which has suffered damage through injury or disease, such as a wound, ulcer, abscess, or tumour.
- **Lordosis:** Excessive inward curvature of the spine.
- **Osteomyelitis:** Inflammation of bone or bone marrow, usually due to infection.
- **Osteoporosis:** A medical condition in which the bones become brittle and fragile from loss of tissue, typically as a result of hormonal changes, or deficiency of calcium or vitamin D.
- **Pansteatitis:** Yellow fat disease – is a physiological condition in which the body fat becomes inflamed.
- **Peroxidative nature:** Hyaline degeneration with swollen eosinophilic fragmented sarcoplasm, macrophage invasion
- **Rarefaction:** An increase in porosity in the bones.
- **Skeletal dysplasia:** One of a large contingent of genetic diseases in which the bony skeleton forms abnormally during fetal development. Achondroplasia is one form of skeletal dysplasia.
- **Scoliosis:** Abnormal lateral curvature of the spine.
- **Spondylitis:** Inflammation of the joints of the backbone.
- **Spondyloepiphysial dysplasia:** A complex of conditions, possibly genetic in cause, characterized by insufficient growth of the vertebral column and flattened vertebrae, and often involving the epiphyses at the shoulder, resulting in a type of dwarfism.

12. CONCLUSION

Skeletal pathology shows similar clinical appearance as a result of skeletal deformation that to with relatively limited number of pathological entities but a very wide range of genetic, physical and infectious factors have been associated. Investigation of etiology cannot be relied on simple association, but requires the demonstration of cause and effect.

REFERENCES

1. Andrades, J. A., Becerra, J. and Fernandez-Liebrez, P. (1996) skeletal deformities in larval, juvenile and adult stages of cultured gilthead sea bream (*Sparus aurata* L.). *Aquaculture* 141: 1-11.
2. Cahu, C., Zambonino-In fante, J. and Takeuchi, T. (2003) Nutritional components affecting skeletal development in fish larvae. *Aquaculture* 227: 245-258.
3. Ferguson, H.W., poppe, t. and Speare, D. J. (1990) Cardiomyopathy in farmed Norwegian salmon. *Diseases of Aquatic Organisms* 8: 225-231.
4. Markiw, M. E. and Wolf, K. (1983) *Myxosoma cerebralis* etiologic agent of salmonid whirling disease requires tubificid worm (Annelida: Oligochaeta) in its life cycle. *Journal of protozoology* 30:561-564.
5. Poppe, T.T., Hastein, T., Frosli, A., Koppang, N. and Norheim, G. (1986) Nutritional aspects of haemorrhagic syndrome in farmed Atlantic Salmon *Salmo salar*. *Diseases of Aquatic Organisms* 1:155-162.
6. Roberts, J. R. (2012) *Fish pathology*. Wiley-Blackwell. pp 581.
7. Witten, P.E., Hansen, A. and Hall, B. K. (2001) Features of mono- and multinucleated bone resorbing cells of the Zebrafish *Danio rerio* and their contribution to skeletal development, remodeling, and growth. *Journal of Morphology* 250: 197-207.
8. Yokoyama, H., freeman, M. A., Yoshinaga, t. and Ogawa, K. (2004) *Myxobolus buri*, the myxosporean parasite causing scoliosis of yellowtail, is synonymous with *Myxobolus acanthogobii* infecting the brain of the yellowfin goby. *Fisheries Science* 70: 1036-1042.